J Hand Microsurg (January–June 2012) 4(1):30–31
DOI 10.1007/s12593-011-0049-4

LETTER TO THE EDITOR

Necessities in Clinical Photography

J. J. Watson · J. Anuradha · S. Raja Sabapathy

Received: 21 July 2011 / Accepted: 25 July 2011 / Published online: 5 November 2011

Sir,
Clinical photography enhances medical records and is essential for the daily practice of surgeons. Important uses of photographs include patient counselling, audit, publications, education, medico-legal work and for planning treatment without repeatedly redressing the wound. The value of such photographs are realised when they are needed, no doubt we have all been painfully aware of this when preparing for presentations.

To assess and improve the quality of the photography at our unit, a retrospective audit was carried out. The criteria used to judge each photograph variable is noted below with our results; which could provide a useful reminder to your readers.

Overview: Over a seven day period, 349 images were studied from 104 patients.

Resolution: Two Mega-pixels (1600×1200) is sufficient for small printouts for medical journals and PowerPoint presentations (*100% achieved).*

Lighting: Illumination should be natural, with details highlighted and not bleached (i.e. no theatre lights). A 'flash' should not be captured reflecting from the retina (red reflex) or from X-rays *(97% achieved).*

Linear scales: When used, their size appropriate for the lesion and denominations should be visible *(79% achieved).*

Focus: The point of interest should be the point of clarity *(97% achieved).*

Positioning (Fig. 1): The lesion should be central, perpendicular to line of sight, framed symmetrically by its background and have an anatomical reference *(93% achieved).*

Background (Figs. 1 and 2a, b): Green or white backgrounds are ideal, examiners hands should be in gloves, distractions should be out of view (i.e. no surgical equipment) and both jewellery and clothes removed *(85% achieved).*

Tidiness (Fig. 1): The subject and background material should be as clean as possible. In operative shots blood should be cleaned from skin and drapes *(92% achieved).*

Completeness: Patient cases should include pre-operative, intra-operative and post-operative photographs and copies of radiological investigations. There must be a reference and date on the photo or print *(74% achieved).*

Standardisation (Figs. 2a, b and 3a, b): Most categories mentioned above should be standardised, such as the positioning/orientation of the subject and the background colour chosen. Consistency of a series allows the comparison of lesions over time and pleasant viewing when presenting publicly *(84% achieved).*

After audit completion, a protocol for photographs in our unit was set using the audit criteria above and a subsequent improvement in these parameters was seen.

The authors thank Mr Chris Davis for the help in preparing this manuscript.

J. J. Watson (✉) · J. Anuradha · S. R. Sabapathy
Department of Plastic, Hand, Reconstructive Microsurgery and Burns Surgery, Ganga Hospital,
313, Mettupalayam Road,
Coimbatore, Tamil Nadu, India
e-mail: email@jaywatson.co.uk

Fig. 1 Illustrates a poor subject position and an untidy field of view

Fig. 2 Backgrounds used are adequate however not standardised over time. Clothing should not be visible

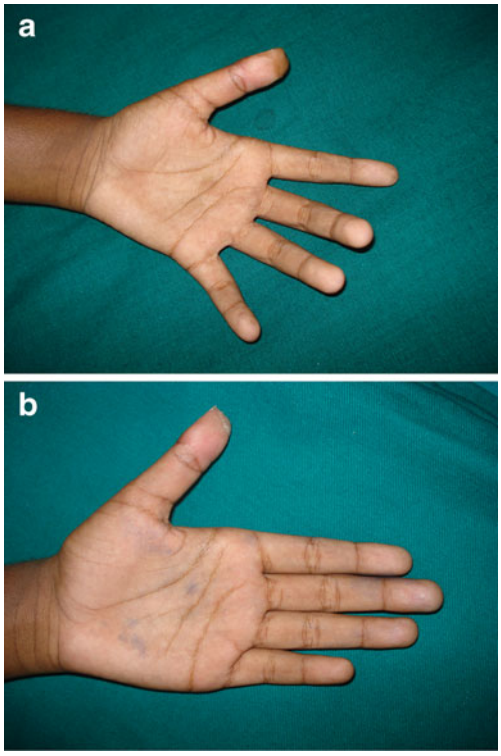

Fig. 3 Poor standardisation of photographs