Forequarter Replantation

S. Raja Sabapathy, MS, MCh, DNB,* Hari Venkatramani, MS, MCh,* J. Dheenadhayalan, MS, DNB,† Praveen Bhardwaj, MS,* Dafang Zhang, MD,‡ S. Rajasekaran, MS, MCh, DNB, PhD†

Traumatic forequarter amputations are rare injuries in which the arm, clavicle, scapula, and proximal shoulder muscles are avulsed from the body. Historically, forequarter amputation has been treated with hemorrhage control, wound debridement, and soft tissue coverage. To our knowledge, successful forequarter replantation has not been previously reported. We present a rare case of forequarter amputation treated successfully with replantation. At the 4.5-year follow-up after replantation, the patient had antigravity elbow flexion, modest shoulder elevation, modest extrinsic finger function, and crude sensation. We discuss relevant technical considerations that indicate that, despite challenges, forequarter replantation can be achieved with success. *(J Hand Surg Am. 2021;■(■):1.e1-e5. Copyright © 2021 by the American Society for Surgery of the Hand. All rights reserved.)*

Key words Amputation, forequarter, major limb, replantation, revascularization.

Online Exclusive

Traumatic forequarter amputations are rare injuries in which the arm, clavicle, scapula, and proximal shoulder muscles are avulsed from the body. Traditionally, the recommended treatment for forequarter amputation has been hemorrhage control with ligation of vessels, wound debridement, and soft tissue coverage.[1] To our knowledge, successful forequarter replantation has not been reported.[2] We present a rare case of forequarter amputation treated successfully with replantation.

CASE REPORT

A 20-year-old right-handed man presented to our hospital 3 hours after a major left upper limb amputation. The patient's left upper limb was crushed and avulsed by a conveyor belt machine, resulting in a forequarter-level amputation (Fig. 1). The amputated part was brought well preserved in a bag surrounded by ice (Fig. 2). The patient was taken directly to the anteroom of the operating room for assessment, resuscitation, and pain relief.[3]

On primary survey, the airway was clear, and breathing was spontaneous. The patient had a blood pressure of 100/60 mm Hg and pulse rate of 49 per minute with notable pallor on inspection. The Glasgow Coma Scale score was 15 on presentation. Concomitant injuries included a left pneumothorax treated with placement of a chest tube. The patient was intubated and resuscitated with 5 units of packed red blood cells, 4 units of fresh frozen plasma, and 1.5 L of crystalline fluids. During resuscitation, the amputated part was examined, and a decision was made to attempt replantation upon finding axillary vessels and radial and ulnar nerves.

The patient was on the operation table within 35 minutes of arrival. Surgery was performed under general anesthesia. The amputated part was debrided, inspected, and kept cool with ice bags wrapped around the part. Prophylactic compartment fasciotomies are often performed in cases of prolonged ischemia time but were deferred in this case because

*From the *Department of Plastic, Hand and Reconstructive Microsurgery, Ganga Hospital, Coimbatore, Tamil Nadu, India; the †Department of Orthopaedic Surgery, Ganga Hospital, Coimbatore, Tamil Nadu, India; and the ‡Department of Orthopaedic Surgery, Brigham and Women's Hospital, Boston, MA.*

Received for publication November 6, 2020; accepted in revised form July 16, 2021.

No benefits in any form have been received or will be received related directly or indirectly to the subject of this article.

Corresponding author: S. Raja Sabapathy, MS, MCh, DNB, Department of Plastic, Hand and Reconstructive Microsurgery, Ganga Hospital, 313, Mettupalayam Road, Coimbatore, Tamil Nadu, 641043, India; e-mail: rajahand@gmail.com.

0363-5023/21/■ ■-0001$36.00/0
https://doi.org/10.1016/j.jhsa.2021.07.038

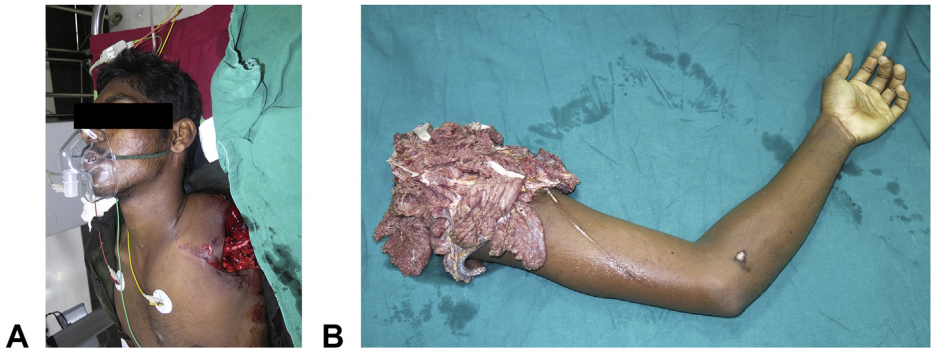

FIGURE 1: Clinical photographs demonstrate **A** the traumatic forequarter amputation residuum and **B** avulsed upper limb at the time of injury.

FIGURE 2: Injury plain radiograph of the amputated part demonstrating forequarter amputation through the level of the clavicle and scapula.

the ischemia time was thought to be short. The amputation was at the level of the distal clavicle and scapula with avulsions of the deltoid, pectoralis major, and latissimus dorsi muscles. The axillary artery, vein, and radial and ulnar nerves were identified. The distal clavicle and proximal humerus were partially resected and primarily fused using a 10-hole dynamic compression plate. The axillary artery and vein were repaired using 8-0 Nylon suture for reperfusion. After the repair of the artery and vein, the artery was allowed to flow for 5 minutes, with the vein clamped to wash out metabolites, transfusing as needed. Sodium bicarbonate (8.4% w/v) 1 mEq/kg body weight was given intravenously 3 minutes prior to venous clamp release. The patient was monitored after clamp release, with attention to signs of hyperkalemia on telemetry and myoglobinuria. If these complications occur, it is our practice not to continue replantation. Heparin was not given for this case.[4] Total ischemia time was 4.5 hours. The ulnar and radial nerves were repaired using microsurgical technique. The patient recovered in the microsurgical intensive care unit. His postoperative course was uneventful, and he was discharged after 2 weeks in an orthosis to maintain shoulder abduction.

Bone union was achieved by 6 months after surgery (Fig. 3). After 1 year, the patient regained M4 strength in elbow and wrist extension, M3 strength in wrist flexion, and M4 strength in the ulnar-innervated extrinsic digital flexors. He had no intrinsic recovery, and because the median nerve was not available for repair, his median-innervated muscles remained paralyzed. The patient reported crude sensation in the entire upper limb, except the median-innervated territory, and he had protective sensation in the ulnar 2 digits. At 14 months after replantation, the patient underwent triceps-to-biceps tendon transfer for elbow flexion; side-to-side transfer of the index finger flexor digitorum profundus tendon to the flexor digitorum profundi's of the middle, ring, and little fingers for index finger flexion; and nerve transfer of the dorsal sensory branch of the ulnar nerve to the lateral half of the median nerve at the distal forearm for lateral hand

sensation. Through this surgery, he achieved M4 strength in elbow flexion, and he learned controlled relaxation of elbow flexion with gravity assistance for elbow extension. At 28 months after replantation, the patient underwent a pronation forearm osteotomy, brachioradialis-to-flexor pollicis longus tendon transfer, and metacarpophalangeal joint dorsal capsulotomies of the second through fifth digits. At the final 4.5-year follow-up, the patient had approximately 40° of active shoulder abduction due to scapulothoracic movement (Fig. 4A), antigravity elbow flexion (Fig. 4B; Video E1, available online on the *Journal's* website at www.jhandsurg.org), gravity-assisted elbow extension, M4 strength in wrist extension (Video E2, available online on the *Journal's* website at www.jhandsurg.org), 50% sensation (subjectively reported by the patient) compared with the contralateral side, and the ability to form a fist with an orthosis to prevent metacarpophalangeal joint hyperextension (Fig. 4C, D; Video E3, available online on the *Journal's* website at www.jhandsurg.org). The patient was able to use the replanted upper limb as a functional assist limb and returned to work in a supervisory position. We believe that the patient would benefit functionally from a static claw correction procedure and stabilization of the thumb carpometacarpal joint. The patient will undergo these procedures in the future at his convenience.

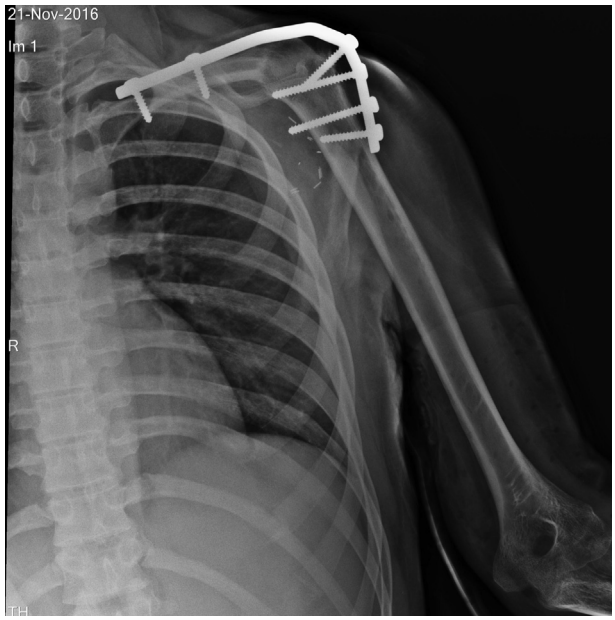

FIGURE 3: Frontal shoulder plain radiograph at the 6-month follow-up demonstrates bony union of the clavicle with the proximal humerus.

DISCUSSION

Traumatic forequarter amputations are rare, devastating injuries in which the arm, clavicle, scapula, and proximal shoulder muscles are avulsed from the body. Historically, difficulties with bony fixation and nerve regeneration were thought to be insurmountable, and the recommended treatment has been hemorrhage control, wound debridement, and soft tissue coverage.[1] Attempted forequarter replantation has been reported by Venkataram et al[2] in an 18-year-old man injured in a cloth-rolling machine. In this case, the ischemia time was 8 hours. Although revascularization was accomplished, the limb was ultimately disarticulated at postoperative day 14 because of sepsis.

Major replantations in general are rare, and they are still rarer proximal to the elbow joint.[5–7] The highest reported level of replantation has been through the shoulder joint.[6] Long-term functional outcomes, both with replantation and with revision amputation and prosthetic rehabilitation, are worse for patients with above-elbow amputations than for patients with below-elbow amputations.[8] However, successful replantation is associated with better scores on the Disabilities of the Arm, Shoulder and Hand assessment and the Michigan Hand Questionnaire than revision amputation and prosthetic rehabilitation.[9] The rate of prosthetic use for patients who undergo above-elbow amputation is less than 50%, and this rate is likely even lower after forequarter amputation.[8] In a series of 20 patients who underwent forequarter amputation for malignancy, Bhagia et al[10] reported that no patient used a prosthesis at follow-up; moreover, the cosmetic disfigurement associated with forequarter amputation may cause considerable psychological distress.

The authors posit that with the appropriate trauma system in place, forequarter replantation can be successfully performed without unduly endangering the patient, and that with secondary reconstructive procedures, a functional assist limb can be expected. There are relevant logistical and technical considerations in forequarter replantation. Limb ischemia time after the patient reaches the replantation center must be minimized, as this is one of the few factors within the treating providers' control in major replantation. Systems that aided our success in this case included around-the-clock availability of senior anesthesiologists and hand surgeons and initial evaluation of the patient in the anteroom of a readily available operating room. We recommend aggressive debridement of avulsed and nonviable muscles, especially muscles on the distal amputated part not likely to regain perfusion after revascularization, to prevent sepsis.

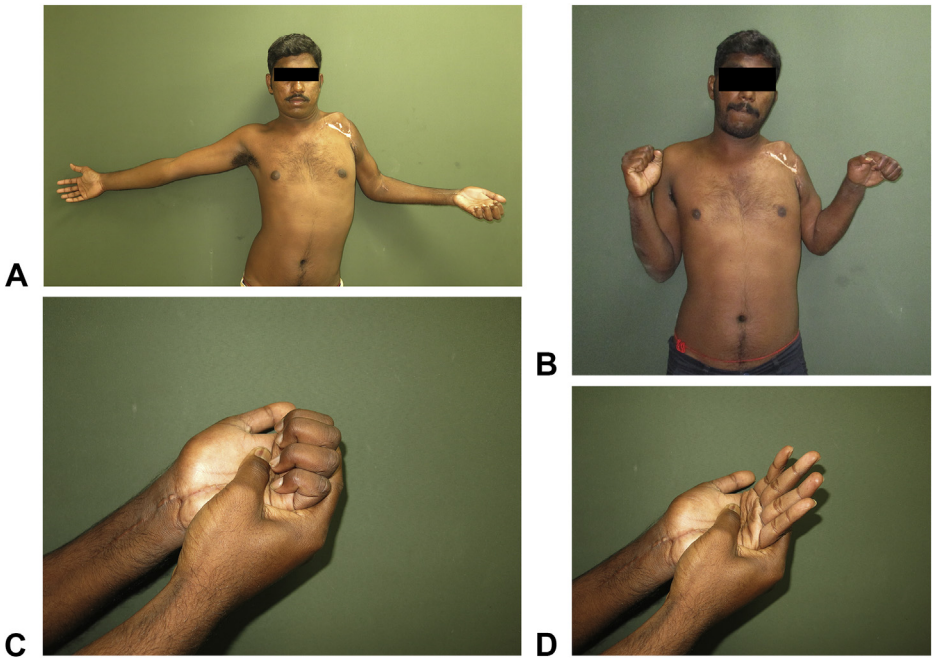

FIGURE 4: Clinical photographs demonstrate **A** shoulder abduction, **B** elbow flexion, **C** finger flexion, and **D** finger extension with metacarpophalangeal joint blocking at the final follow-up.

Fasciotomies should be considered in cases of prolonged ischemia time, and hemostasis should be achieved during debridement of the amputated part. Bony fixation can be especially challenging.[2] Skeletal shortening and expeditious rigid osteosynthesis is paramount to obtaining skeletal stability and allowing for successful revascularization without concern for accidental disruption of the anastomoses. This may entail primary arthrodesis of the proximal humerus to the remaining shoulder girdle. The average ischemia time for successful arm replantation has been reported to be 5.4 hours.[7] Prompt revascularization is crucial to limb survival and to decrease the risk of reperfusion injury. Temporary shunt placement to establish perfusion prior to bony stabilization has been advocated, but it was not used in this case. Since nerve coaptations are performed at an infraclavicular level, meticulous nerve repair can be met with a successful functional outcome. Since skeletal shortening is always performed, nerves can be trimmed to healthy fascicles and repaired without tension in a healthy wound bed.

Secondary procedures after major replantation are expected. Following arm replantation, the number of secondary procedures averages 2.6 per patient, and includes nerve surgery, muscle transfer, tendon transfer, wound coverage, contracture release, joint arthrodesis, and nonunion repair.[7] Restoration of active elbow flexion is a priority, and a secondary procedure to restore this function may be necessary after forequarter replantation. Modest shoulder elevation, modest recovery of the digital extrinsic flexors and extensors, and crude sensation may be seen. The recovery of hand intrinsics is unlikely, and secondary surgery for claw correction may be indicated. Our experience with secondary reconstructive procedures following replantation has allowed us to expand indications for major replantation. Secondary procedures are performed when muscle recovery has reached sufficient strength.

Despite technical and logistical challenges, forequarter replantation can be achieved with success in the appropriate context, and the functional results can be gratifying and superior to alternatives.

REFERENCES

1. Layton TR, Villella ER, Marrangoni AG. Traumatic forequarter amputation. *J Trauma*. 1981;21(5):411–412.
2. Venkataram A, Shetty N, Mashalkar NS, Dsouza N. Forequarter replantation and the lessons learnt. *Plast Reconstr Surg Glob Open*. 2015;3(9):e509.
3. Sabapathy SR Venkateswaran G, Boopathi V, Subramanian JB. "On arrival block"-management of upper extremity trauma with resuscitation in the operating room. *Plast Reconstr Surg Glob Open*. 2020;8(10):e3191.
4. Sabapathy SR, Elliot D, Venkatramani H. Major replantation. In: Boyd B, Jones NF, eds. *Operative Microsurgery*. McGraw Hill; 2015:698–719.
5. Sabapathy SR, Venkatramani H, Bharathi RR, Dheenadhayalan J, Bhat VR, Rajasekaran S. Technical considerations and functional outcome of 22 major replantations (The BSSH Douglas Lamb Lecture, 2005). *J Hand Surg Eur* Vol. 2007;32(5):488–501.
6. Larson JV, Kung TA, Cederna PS, Sears ED, Urbanchek MG, Langhals NB. Clinical factors associated with replantation after

traumatic major upper extremity amputation. *Plast Reconstr Surg*. 2013;132(4):911–919.
7. Wang C, Askari M, Zhang F, Lineaweaver WC. Long-term outcomes of arm replantation. *Ann Plast Surg*. 2020;84(3S suppl 2):S151–S157.
8. Otto IA, Kon M, Schuurman AH, van Minnen LP. Replantation versus prosthetic fitting in traumatic arm amputations: a systematic review. *PLoS One*. 2015;10(9):e0137729.
9. Pet MA, Morrison SD, Mack JS, et al. Comparison of patient-reported outcomes after traumatic upper extremity amputation: replantation versus prosthetic rehabilitation. *Injury*. 2016;47(12):2783–2788.
10. Bhagia SM, Elek EM, Grimer RJ, Carter SR, Tillman RM. Forequarter amputation for high-grade malignant tumours of the shoulder girdle. *J Bone Joint Surg Br*. 1997;79(6):924–926.