

Role of Exploration and Nerve Transfer in Restoration of Shoulder Function in Parsonage-Turner Syndrome

Praveen Bhardwaj^{1,*} Vigneswaran Varadharajan² Aashish Vallurupalli³ Vimal Kumar Kumhari⁴
Hari Venkatramani⁵ S. Raja Sabapathy⁵

¹ Department of Hand and Microsurgery, Ganga Medical Centre and Hospital, Coimbatore, Tamil Nadu, India

² Department of Plastic Surgery, Hand and Reconstructive Microsurgery, Ganga Medical Center and Hospitals Pvt. Ltd., Coimbatore, Tamil Nadu, India

³ Department of Orthopaedics, NRI Medical College, Chinakakani, Andhra Pradesh, India

⁴ Department of Plastic Surgery, Ganga Medical Center and Hospitals Pvt. Ltd, Coimbatore, Tamil Nadu, India

Address for correspondence Praveen Bhardwaj, MBBS, MS, DNB, FNB, EDHS, The Department of Hand and Microsurgery, Ganga Medical Centre and Hospital, 313, Mettupalayam Road, Coimbatore 641043, Tamil Nadu, India (e-mail: drpb23@gmail.com).

⁵ Department of Hand and Microsurgery, Ganga Hospital, Coimbatore, Tamil Nadu, India

J Peripher Nerve Surg 2022–23;6–7:35–40.

Abstract

Aim Parsonage-Turner syndrome (PTS) is a rare but serious condition characterized by spontaneous paresis of the upper extremity, typically lasting for several months with variable recovery. Recent literature reports less optimistic outcome than assumed, with persistent functional impairment in more than half of the patients at 2 years follow-up. Limitation of shoulder abduction is more disabling and the motor recovery needs to be of at least grade 3 to be of functional use. Correction of the residual shoulder deficit is also challenging as the standard tendon transfers for the shoulder abduction provide only modest outcome. However, the modern nerve transfers for the shoulder provide more reliable and better functional outcome. But to be effective they should be performed within 6 to 9 months from the time of onset of the weakness. Knowing that the patients who do not show early recovery are at risk of incomplete recovery in long-term provides a thought that any patient who does not show recovery in 6 to 9 months could be considered for nerve surgery.

Keywords

- ▶ Parsonage-Turner syndrome
- ▶ nerve transfer
- ▶ neuralgic amyotrophy
- ▶ electrical stimulation
- ▶ tendon transfer

Methods We performed nerve surgery in two young male patients with PTS who presented to us at 7 and 8 months with persistent paralysis of shoulder abduction. A combination of neurolysis, tandem stimulation, and nerve transfers was performed based on the intraoperative electrical stimulation findings.

Results Both the patients had satisfactory recovery of shoulder abduction. At 1-year follow-up, they had recovered grade 4 to 5 motor power and had “excellent” outcome based on Narakas grading.

DOI <https://doi.org/10.1055/s-0043-1778135>.
ISSN XXXX-XXXX.

© 2024. Indian Society of Peripheral Nerve Surgery. All rights reserved.

This is an open access article published by Thieme under the terms of the Creative Commons Attribution-NonDerivative-NonCommercial-License, permitting copying and reproduction so long as the original work is given appropriate credit. Contents may not be used for commercial purposes, or adapted, remixed, transformed or built upon. (<https://creativecommons.org/licenses/by-nc-nd/4.0/>)

Thieme Medical and Scientific Publishers Pvt. Ltd., A-12, 2nd Floor, Sector 2, Noida-201301 UP, India

Conclusion PTS patients with shoulder paralysis can be offered nerve surgery if they fail to show recovery in 6 to 9 months since onset of symptoms as late reconstruction with tendon transfers gives only modest outcome. Nerve surgery in the form of neurolysis, electrical stimulation, and nerve transfers provided good outcome in our patients with recovery of shoulder function to normalcy.

Introduction

Parsonage-Turner syndrome (PTS) also known variably as acute brachial plexus neuritis, neuralgic amyotrophy, mononeuritis multiplex, and shoulder girdle syndrome is a rare clinical entity with clinical presentation of sudden onset of severe pain around shoulder and/or arm followed by sudden weakness and atrophy of shoulder girdle muscles following a variable period. Although Dreschfeld¹ described it first in 1887, it was named after M J Parsonage and J W Aldren Turner² after their index publication with 136 cases in *Lancet* in 1948. Since then, many authors have published on the etiology, prognosis, and management.³⁻⁷ However, an uncertainty about the management plan for these patients, especially with regard to nerve surgery, still persists.

The reported incidence of PTS varies greatly, from 1 to 2 per 100,000 per year to 20 to 30 per 100,000 per year, because of a lack of clarity about diagnostic criteria and the possibility of spontaneous recovery.⁸⁻¹³ Hand surgeons typically tend to see these patients quite late as widely prevailing belief about spontaneous recovery encourages physicians to continue with observation. However, recent literature reports residual deficits in as high as two-third of the patients even after 3 years.¹¹⁻¹⁸ Moreover, it has been observed that the patients who show early recovery are the only ones who tend to recover completely, whereas others may remain disabled with no or incomplete recovery. Especially at the shoulder, the functional deficits are more disabling and the motor recovery needs to be of at least grade 3 to be of functional use. Correction of the residual shoulder deficit is also challenging as the standard tendon transfers for the shoulder abduction provide only modest outcome. On the other hand, modern nerve transfers for the shoulder provide more reliable and better functional outcome.¹⁹ But to be effective they should be performed within 6 to 9 months from the time of onset of the weakness.

The recovery pattern observed in patients in PTS and the outcome of nerve/tendon surgery for shoulder abduction in our experience while managing cases of brachial plexus injuries gives a thought that the patients who do not show recovery in first 6 months could be offered a nerve surgery between 6 and 9 months, while those who show some recovery could be observed to correct the residual deficit with tendon transfer surgery once the recovery has plateaued. We have performed nerve transfers for shoulder abduction and external rotation in two such patients who presented to us with shoulder paralysis with no recovery in a

“good time period” for the nerve transfer surgery and herein we report the outcome of these two cases. Also outlined are the current concepts related to etiology, diagnosis, prognosis, and our management strategy for these cases.

Materials and Methods

Case 1

A 24-year-old male presented to us in June 2017 with complaints of right shoulder weakness for 7 months. The weakness followed a brief episode of severe pain around the shoulder and there was no history of trauma. Patient did not notice any recovery in 7 months and had obvious wasting of the deltoid muscle. He underwent magnetic resonance imaging (MRI) of the shoulder and electromyography (EMG). MRI scan did not reveal any nerve injury or fibrosis but showed gross atrophy of the deltoid muscle. EMG study also did not reveal any evidence of recovery in the deltoid muscle. Patchy recovery of the supraspinatus muscle was noted on EMG; however, the patient did not have any shoulder abduction power clinically. Active external rotation was possible, and it was of MRC (Medical Research Council) motor grade 2. After a detailed discussion with the patient and parents regarding the continuation of the conservative management and the merits and demerits of surgical intervention, the patient was planned for exploration of the brachial plexus and possible nerve transfers to restore shoulder abduction.

On exploration, we did not find any nerve lesion in the C5 root, upper trunk or the suprascapular and axillary nerves. On intraoperative electrical stimulation, we noted that supraspinatus muscle showed response to the lowest stimulus of 1 mA and anterior division of the axillary nerve also showed response to the stimulus; however, there was no response noted in the posterior division of the axillary nerve to any level of electrical stimulation. The suprascapular and anterior divisions of the axillary nerves were neurolysed and stimulated with 5 mA for 20 minutes and the long head of triceps motor branch was transferred to posterior division of the axillary nerve. The limb was immobilized in an arm sling for a month and following which shoulder mobilization and electrical stimulation of the shoulder abductors were started.

At the 4-month follow-up, the patient showed clinical recovery of supraspinatus, infraspinatus, and deltoid muscles. Patient started showing good recovery of shoulder abduction at 4 months post-surgery and at the 6-month follow-up, he had recovered full range of shoulder abduction and external rotation and the motor power of abduction was

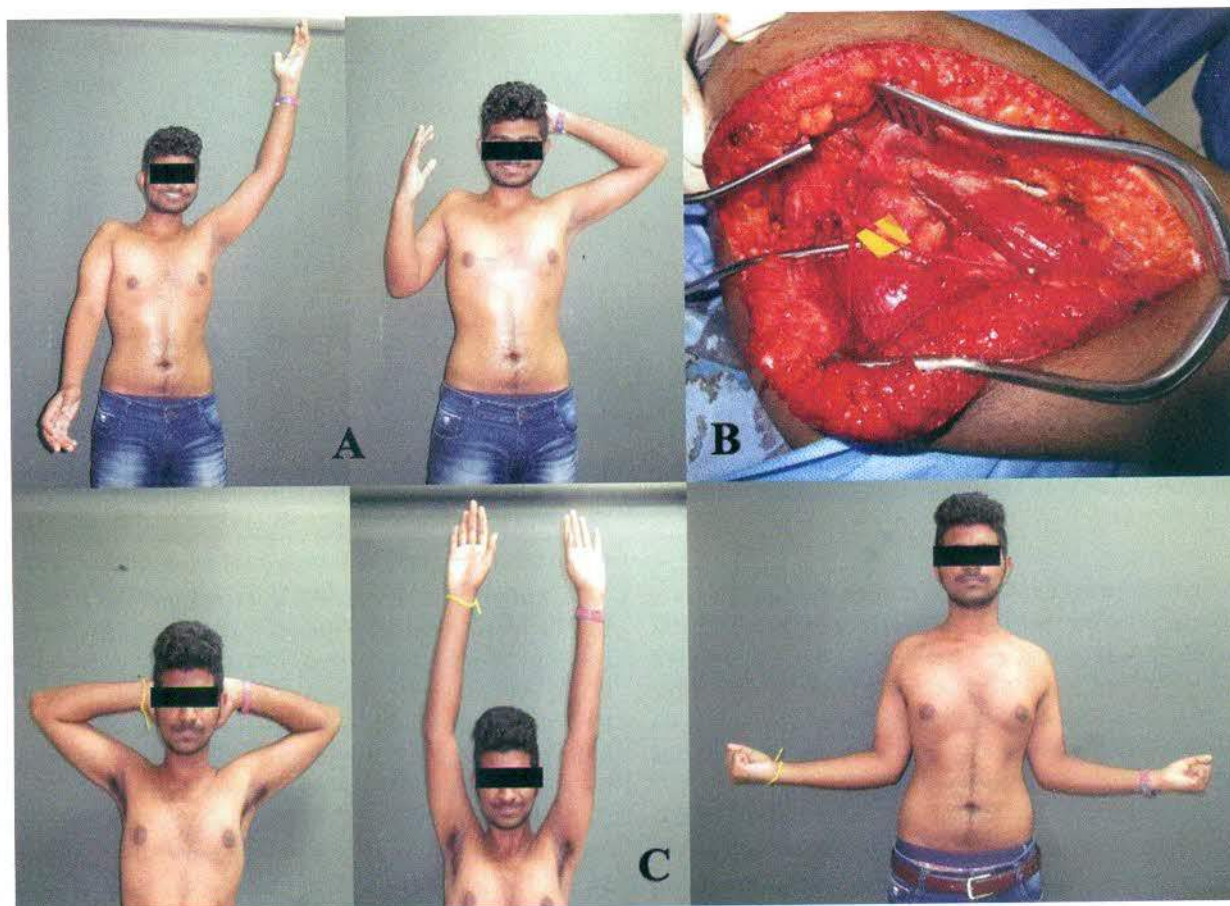


Fig. 1 (A) A 24-year-old male presented with right shoulder weakness for 9 months duration developed following intense physical activity. (B) He underwent exploration, neurolysis, and brief electrical stimulation to suprascapular nerve and anterior division of axillary nerve and transfer of long head of triceps motor branch to posterior division of axillary nerve. (C) Narakas excellent grade recovery at 6 months follow-up.

recorded as MRC grade 4. The deltoid muscle bulk and strength further improved and at the 1-year follow-up, the patient had a normal contour of the deltoid region with MRC grade 5 motor power and was graded as excellent according to Narakas²⁰ functional outcome grading (–Fig. 1).

Case 2

A 21-year-old male presented to us with weakness of the shoulder movements for 8 months in December 2017. He gave a history of severe pain around the shoulder after strenuous physical activity followed by inability to move the shoulder. On clinical examination, he had no shoulder abduction; however, MRC grade 2 external rotation was present. The deltoid clinically appeared to be wasted and no contraction was palpable. His MRI scan did not reveal any nerve lesion. EMG study revealed total paralysis of the supra- and infraspinatus muscles with no recovery and only mild patchy recovery of the deltoid.

On surgical exploration, axillary nerve showed response to electrical stimulus of 1 mA; however, suprascapular nerve (SSN) did not show any response to even the largest stimulation strength of 5 mA. Axillary nerve was neurolysed and stimulated with 5 mA stimulus for 20 minutes and the spinal accessory nerve was transferred to the SSN to innervate the paralyzed supra- and infraspinatus muscles.

Patient showed appreciable recovery at the 4-month follow-up and at 1-year follow-up he had full range of shoulder abduction and external rotation and the motor power was graded as 4+. He also achieved an “excellent” grade on Narakas outcome score for shoulder²⁰ (–Fig. 2).

Results

Both the patients presented with the classical presentation of PTS with intense pain around the shoulder girdle followed by paralysis of shoulder abductors. They failed to show any recovery of shoulder abduction at their presentation at 7 and 8 months post onset of symptoms. Hence, we offered them option of surgical intervention and we performed neurolysis, electrical stimulation, and nerve transfers as detailed above.

The patients started showing recovery after 4 months with resolution of pain and improvement in shoulder abduction. At 1-year follow-up both had shoulder abduction power of MRC grade 4 and excellent outcome according to Narakas²⁰ grading.

Discussion

The symptoms leading to paralysis and the recovery pattern of PTS are variable. Many neurological and musculoskeletal

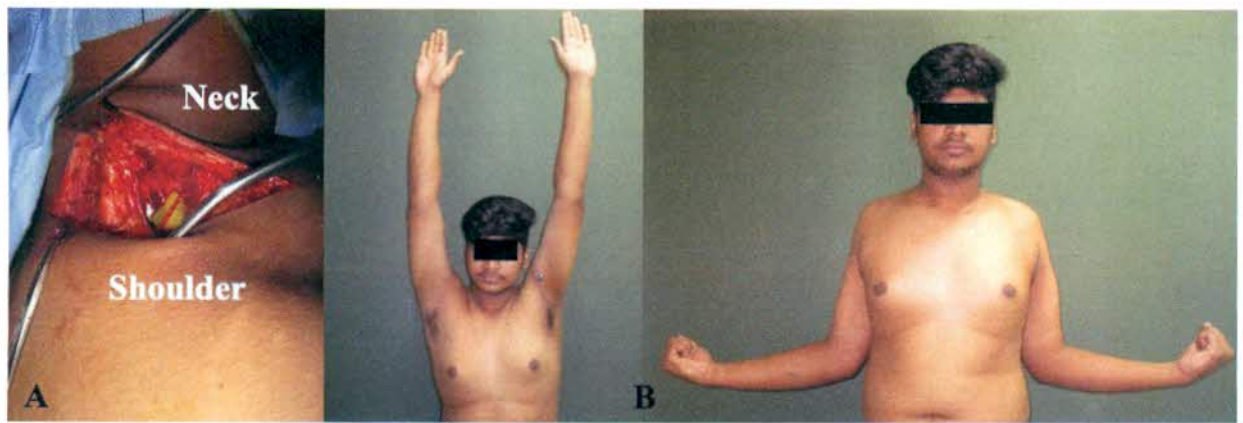


Fig. 2 (A) A 17-year-old male who presented to us with weakness of right shoulder following strenuous exercises and pain underwent exploration neurolysis of axillary nerve and spinal accessory nerve to suprascapular nerve transfer (B) Narakas excellent grade shoulder recovery at 1-year follow-up.

differentials need to be ruled out and often the diagnosis is of exclusion. Taking into account the rarity of the problem, it is commonly misdiagnosed and the diagnosis has a reported mean delay of up to 90 days or more with at least three consultations.²¹ Furthermore, the management strategies are unclear leading to lifelong disability for the patients who fail to recover spontaneously.

In 1942, Parsonage and Turner published their landmark article—"Neuralgic Amyotrophy – The Shoulder Girdle Syndrome," wherein they reviewed 136 patients about the etiology, pattern of involvement, and prognosis of the disease.² They stated that the prognosis was usually good with satisfactory recovery within 6 months in patients who have recovered some voluntary power within first 3 to 4 weeks, or in whom the muscles are not completely paralyzed during initial acute attack. Patients who show late recovery at about 9 to 12 months following onset can continue to recover up to 2 years or even more but eventually recover. Later, other investigators like Tsairis et al⁶ in 1972, Tonali et al¹⁸ in 1983, and Cruz-Martínez et al²² in 2002 have observed that on average 80 to 90% of patients would recover satisfactorily by 2 to 3 years from the onset of paralysis.

More recent articles, however, do not report such uniformly good outcomes probably because of more strict assessment parameters. Van Alfen et al¹¹ reviewed clinical spectrum of 246 cases of PTS that included both idiopathic neuralgic amyotrophy (INA) and hereditary neuralgic amyotrophy (HNA). They observed that recovery was not of good quality and they reported that only 34.8% of those suffering from INA and 33.3% afflicted by HNA had made 90 to 99% recovery. They reported that in INA patients mild paresis was still present in 69.4% cases, moderate paresis in 13.9%, and severe in paresis in 2.8%. The outcome of HNA was even worse: 40% had mild paresis, 30% had moderate paresis, and 20% had severe paresis, as assessed by the patients themselves. They stated that recovery was less favorable than usually assumed as persisting pain and paresis was seen in approximately two-thirds of patients who were followed for 3 years or more.¹¹ Two-thirds of the patients at 2 years reported impairments in daily life.¹²

Recovery in cases with PTS depend upon the axonal loss that had occurred during the acute phase of paralysis. When the muscle gets denervated, reinnervation occurs in two ways: with collateral sprouting from the unaffected axons or by regeneration of injured axon.²³ In injuries with 20 to 30% of the axonal loss, collateral sprouting that occurs at neuromuscular junction is the primary mechanism of recovery. Collateral sprouting begins in the first 4 days after injury and continues for approximately 3 to 6 months. If the amount of axonal loss is more than 70%, then the collateral reinnervation is not sufficient for an adequate recovery and in these cases proximal reinnervation is required.

The role of nerve surgery in PTS has been debated for long. Both the timing and the type of nerve surgery remain controversial. Though nonoperative management still is widely followed, some authors have found more reliable results with intervention in the form of nerve surgery. Deriving any conclusions from the literature is difficult as the indications would differ for the nerve involved and the extent of involvement. For anterior interosseous nerve, Nagano recommended that exploration of the involved nerve should be offered to the patients who did not show any signs of recovery by 3 months after onset.²⁴ Whereas, for long thoracic nerve mononeuritis, Ray et al recommended nerve surgery if satisfactory recovery was not noted by 7 months.²⁵ The indication for nerve surgery is based on the experience that the nerve surgery provides much better outcome than the tendon/muscle transfer or slings / bony procedures if the motor deficit fails to recovery spontaneously.²⁵ We believe that a waiting period of 6 to 9 months gives sufficient time for expected spontaneous recovery and also is within the suitable time for effective motor reinnervation given the time critical nature of motor end plates. We reserve tendon transfers for patients who fail to recover completely by 2 years.

Nerve surgery could be indicated more for involvements where the motor deficits, if not recovered completely, are difficult to correct effectively by tendon transfer surgery, such as paralysis of shoulder abduction. If spontaneous recovery fails to provide more than grade 3 motor power for shoulder abduction, the patient would have significant

functional disability. However, at the time of 2 to 3 years, the available options of trapezius transfer or shoulder fusion give only modest outcome and patient would be left with lifelong disability. On the other hand, modern nerve transfers provide more reliable recovery of shoulder abduction, especially in younger patients. Both of our patients presented here were young males (24 years and 21 years) and reported to us after inadequate spontaneous recovery at 7 and 8 months since the onset of the weakness. Surgical intervention in both these cases resulted in excellent outcome.

The type of nerve surgery applied to various nerves involved in PTS also remains controversial. Most commonly applied nerve surgery in literature is neurolysis and has been found to be effective. Nagano achieved good results with neurolysis of the anterior interosseous nerve.²⁴ The role of neurolysis and brief tandem electrical stimulation in cases of idiopathic neuritis and nerve in continuity lesions especially in compressive neuropathies have been described experimentally on rat models by Brushart et al,²⁶ Sobotka et al,²⁷ Al-Majed et al,²⁸ Shapira et al,²⁹ and others.³⁰ Clinically the role of electrical stimulation was documented by Nath and Melcher³¹ in the recovery of serratus anterior and by Gordon et al^{32,33} in patients with carpal tunnel syndrome. The exact duration and quantity of electrical stimulation to be given were not quantified. The role of electrical stimulation was by enhancing the axonal regeneration, preferential motor regeneration mainly by enhancing the release of neurotransmitters especially brain-derived nerve factor), neurotrophin 4/5 in a short term, and thereby resulting in formation of novel neural circuits in the long-term. These neurotransmitters result in increased cytoskeleton that include actin and tubulin synthesis which are important in axonal regrowth. Both of our cases showed much earlier recovery of shoulder abduction (4 months) than expected from a nerve transfer indicating that the neurolysis results in earlier recovery and then the recovery was further augmented once the nerve transfer recovered the innervated muscle.

Pan et al³⁴ reported hourglass constriction of the involved nerve in five patients of PTS who were not responding to conservative management and underwent exploration. They reported hourglass constriction of the involved nerve in all the patients without any constriction bands or muscles compressing them. They reported best results with neurolysis and incomplete recovery when a nerve graft was required to bridge the gap after resection of the constriction.³⁴ Similar hourglass constrictions were reported by Oberlin et al³⁵ in the axillary nerve of two patients with isolated deltoid paralysis. We did not observe any constriction or pathology in the nerves in both of our cases.

We could not find much literature regarding the nerve transfers for the improvement in shoulder abduction in PTS. Nevertheless, Ray et al²⁵ reported a case of two-level nerve transfer for the treatment of long thoracic nerve palsy that failed to recover spontaneously at 7 months of its onset. Nerve transfers provided excellent result in their case and authors recommended nerve transfer for patients who failed to recover at 7 months.²⁵ In our two cases, we performed neurolysis of the nerves that showed response to electrical

stimulation and performed nerve transfer when the nerve did not show any response to intraoperative stimulation. Both cases achieved complete motor recovery and excellent functional outcome at the shoulder.

Encouraged with the excellent outcome in these two cases, we presently offer the nerve surgery option to all the patients who present to us with persistent weakness of the shoulder for 6 to 9 months with no satisfactory clinical and EMG evidence of recovery. Intraoperative stimulation is crucial in the final decision making; if the involved nerve shows a response to the lowest stimulus of 1 mA, it is managed by neurolysis and tandem electrical stimulation for 20 minutes with 5 mA; however, if the involved nerve does not show a response to the highest stimulus of 5 mA, it is considered for nerve transfer. Spinal accessory nerve is our choice for the SSN transfer and the long head triceps motor branch for the axillary nerve.

Conclusion

The observed recovery pattern in the cases of PTS wherein patients who show early recovery have good outcomes eventually while the patients who show late recovery have unpredictable final outcomes gives us a window of opportunity to perform nerve surgery to get a reliable outcome. Given that the tendon transfers at the shoulder provide only modest function and nerve transfers can be offered only till 9 months from the onset of weakness, we suggest considering nerve surgery for patients with PTS who fail to show recovery during 6 to 9 months. Nerve surgery in the form of neurolysis, electrical stimulation, and nerve transfers provided good outcome in our patients with recovery of shoulder function to normalcy.

Ethical Approval and Consent to Participate

Informed consent obtained from the patients and ethical approval obtained.

Consent for Publication

Not applicable.

Authors' Contributions

None.

Availability of Data and Materials

Not applicable.

Financial Support and Sponsorship

None.

Funding

None.

Conflicts of Interest

None declared.

References

- 1 Dreschfeld J. On some of the rarer forms of muscular atrophies. *Brain* 1886;9(02):178–195

- 2 Parsonage MJ, Turner JW. Neuralgic amyotrophy; the shoulder-girdle syndrome. *Lancet* 1948;1(6513):973-978
- 3 Burnard ED, Fox TG. Multiple neuritis of the shoulder girdle. A report of nine cases occurring in the 2nd New Zealand Expeditionary Force. *N Z Med J* 1942;43:241-247
- 4 Allen I. The neurological complications of serum treatment with report of a case. *Lancet* 1931;218(5647):1128-1131
- 5 Spillane J. Localised neuritis of the shoulder girdle. A report of 46 cases in the MEF. *Lancet* 1943;242(6270):532-535
- 6 Tsairis P, Dyck PJ, Mulder DW. Natural history of brachial plexus neuropathy. Report on 99 patients. *Arch Neurol* 1972;27(02):109-117
- 7 Bardos V, Somodská V. Epidemiologic study of a brachial plexus neuritis outbreak in northeast Czechoslovakia. *World Neurol* 1961;2:973-979
- 8 Beghi E, Kurland LT, Mulder DW, Nicolosi A. Brachial plexus neuropathy in the population of Rochester, Minnesota, 1970-1981. *Ann Neurol* 1985;18(03):320-323
- 9 MacDonald BK, Cockerell OC, Sander JW, Shorvon SD. The incidence and lifetime prevalence of neurological disorders in a prospective community-based study in the UK. *Brain* 2000;123(Pt 4):665-676
- 10 van Alfen N, van Eijk JJ, Ennik T, et al. Incidence of neuralgic amyotrophy (Parsonage Turner syndrome) in a primary care setting—a prospective cohort study. *PLoS One* 2015;10(05):e0128361
- 11 van Alfen N, van Engelen BG. The clinical spectrum of neuralgic amyotrophy in 246 cases. *Brain* 2006;129(Pt 2):438-450
- 12 van Alfen N, van der Werf SP, van Engelen BG. Long-term pain, fatigue, and impairment in neuralgic amyotrophy. *Arch Phys Med Rehabil* 2009;90(03):435-439
- 13 Feinberg JH, Radecki J. Parsonage-turner syndrome. *HSS J* 2010;6(02):199-205
- 14 Collie AM, Landsverk ML, Ruzzo E, et al. Non-recurrent SEPT9 duplications cause hereditary neuralgic amyotrophy. *J Med Genet* 2010;47(09):601-607
- 15 van Alfen N, Gabreëls-Festen AA, Ter Laak HJ, Arts WF, Gabreëls FJ, van Engelen BG. Histology of hereditary neuralgic amyotrophy. *J Neurol Neurosurg Psychiatry* 2005;76(03):445-447
- 16 van Eijk JJ, van Alfen N, Berrevoets M, van der Wilt GJ, Pillen S, van Engelen BG. Evaluation of prednisolone treatment in the acute phase of neuralgic amyotrophy: an observational study. *J Neurol Neurosurg Psychiatry* 2009;80(10):1120-1124
- 17 van Alfen N, van Engelen BG, Hughes RA. Treatment for idiopathic and hereditary neuralgic amyotrophy (brachial neuritis). *Cochrane Database Syst Rev* 2009;2009(03):CD006976
- 18 Tonali P, Uncini A, Di Pasqua PG. So-called neuralgic amyotrophy: clinical features and long term follow-up. *Ital J Neurol Sci* 1983;4(04):431-437
- 19 Zhang D, Varadharajan V, Bhardwaj P, Venkatramani H, Sabapathy SR. Considerations in the selection of donor nerves for nerve transfer for reanimation of elbow and shoulder in traumatic brachial plexus injuries. *J Hand Surg Asian Pac Vol* 2022;27(01):10-21
- 20 Narakas AO In: Operative Nerve Repair and Reconstruction. Gelberman R, editor. Philadelphia: Lippincott Williams and Wilkins Company; 1991. Neurotization in the treatment of brachial plexus injuries
- 21 Chisholm K, Scala S, Srinivasan J. Delay in diagnosis of neuralgic amyotrophy in patients initially evaluated by non-neurologists. *Eur J Neurol* 2008;15(03):e18
- 22 Cruz-Martínez A, Barrio M, Arpa J. Neuralgic amyotrophy: variable expression in 40 patients. *J Peripher Nerv Syst* 2002;7(03):198-204
- 23 Menorca RM, Fussell TS, Elfar JC. Nerve physiology: mechanisms of injury and recovery. *Hand Clin* 2013;29(03):317-330
- 24 Nagano A. Spontaneous anterior interosseous nerve palsy. *J Bone Joint Surg Br* 2003;85(03):313-318
- 25 Ray WZ, Pet MA, Nicoson MC, Yee A, Kahn LC, Mackinnon SE. Two-level motor nerve transfer for the treatment of long thoracic nerve palsy. *J Neurosurg* 2011;115(04):858-864
- 26 Brushart TM, Hoffman PN, Royall RM, Murinson BB, Witzel C, Gordon T. Electrical stimulation promotes motoneuron regeneration without increasing its speed or conditioning the neuron. *J Neurosci* 2002;22(15):6631-6638
- 27 Sobotka S, Chen J, Nyirenda T, Mu L. Intraoperative 1-hour electrical nerve stimulation enhances outcomes of nerve-muscle-endplate band grafting technique for muscle reinnervation. *J Reconstr Microsurg* 2017;33(08):533-543
- 28 Al-Majed AA, Neumann CM, Brushart TM, Gordon T. Brief electrical stimulation promotes the speed and accuracy of motor axonal regeneration. *J Neurosci* 2000;20(07):2602-2608
- 29 Shapira Y, Sammons V, Forden J, et al. Brief electrical stimulation promotes nerve regeneration following experimental in-continuity nerve injury. *Neurosurgery* 2019;85(01):156-163
- 30 Park BR, Hwang JH, Kim MS, Lee MY, Rhee JK, Lee SH. Modulation of BDNF expression by electrical stimulation in hindlimb muscles of rats. *Neurosci Res Commun* 2004;34(01):10-19
- 31 Nath RK, Melcher SE. Rapid recovery of serratus anterior muscle function after microneurolysis of long thoracic nerve injury. *J Brachial Plex Peripher Nerve Inj* 2014;2(01):4
- 32 Gordon T, Amirjani N, Edwards DC, Chan KM. Brief post-surgical electrical stimulation accelerates axon regeneration and muscle reinnervation without affecting the functional measures in carpal tunnel syndrome patients. *Exp Neurol* 2010;223(01):192-202
- 33 Chan KM, Curran MWT, Gordon T. The use of brief post-surgical low frequency electrical stimulation to enhance nerve regeneration in clinical practice. *J Physiol* 2016;594(13):3553-3559
- 34 Pan Y-W, Wang S, Tian G, Li C, Tian W, Tian M. Typical brachial neuritis (Parsonage-Turner syndrome) with hourglass-like constrictions in the affected nerves. *J Hand Surg Am* 2011;36(07):1197-1203
- 35 Oberlin C, Shafi M, Diverres J-P, Silberman O, Adle H, Belkhezar Z. Hourglass-like constriction of the axillary nerve: report of two patients. *J Hand Surg Am* 2006;31(07):1100-1104