Technical Tips in Managing Fingertip Injuries

Hari Venkatramani, Gururaj Hosahalli, S Raja Sabapathy

Email: rajahand@gmail.com

1) When do you do flaps for fingertip injuries?

We use flaps for fingertip injuries when the bone is exposed either through amputation or through slicing injury which causes soft tissue loss. However, in the literature or experience of a number of people many could be treated conservatively, in our set up we feel comfortable to practice conservative treatment only for children below five years.

2) When do you suture the amputated tip without microvascular repair (composite graft)?

We suture back the amputated fingertip (up to middle of the nailbed) without microvascular repair for children below five years. The wound would need debridement before attaching the composite graft. Fat is excised from the graft as much as possible and the tip sutured with 6.0 chromic catgut. A compression tie over dressing is then done.

Sometimes the sutured tip becomes dark, but as long as it is sticky, it is left attached. Sometimes a part of the graft takes up the scar tissue at the base pulls up the intact skin so that the tip is covered with sensate and good skin.

It has been the experience that time from injury to surgery is a determinant for success just like replantation, even though the tip is not revascularised[1]. Keeping the amputated tip cooled till attachment also helps.

Dr S Raja Sabapathy

Chairman, Division of Plastic Surgery, Hand Surgery, Reconstructive Microsurgery & Burns.

Ganga Hospital, 313, Mettupalayam Road, Coimbatore - 641 043, INDIA

3) What are the commonly used flaps?

The straight V-Y advancement flap[2] (Straight triangular flap) and the oblique V –Y advancement flaps[3] (Oblique triangular flap) are the commonly used flaps **(Figure 1)**.

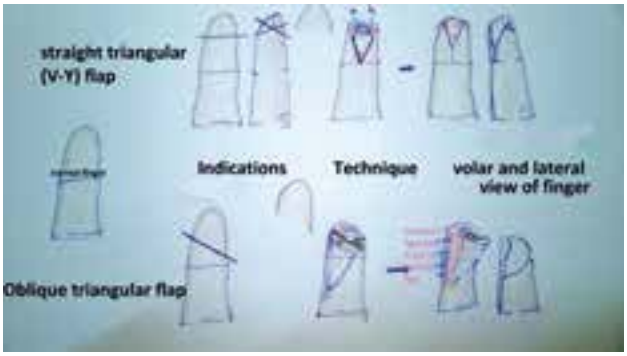

Figure 1: Upper row of diagram showing straight triangular flap and lower row of diagrams showing oblique triangular flap. Indications for straight triangular flap being transverse amputation, dorsal oblique amputation and volar oblique amputations upto 30-35 degree angulation. Indications for oblique triangular flap being oblique amputations in the more proximal location.

Technical tips in doing straight triangular flaps

a) Choose it for dorsal oblique, transverse amputation and palmar oblique injuries that angle upto 30-35 degrees.

b) The breadth of the advancing flap should be equivalent to the distance between the two lateral nail folds **(Figure 2).** If flap is raised beyond this, after advancement, redundant tissue in the edges will have to be excised. Secondly, it also does not give a good aesthetic appearance.

c) Start the incision perpendicular to the wound for about 4 to 5mm, and then make the bend to create the apex of the triangle (**Figure 3, Figure 4**). In this way blood supply to the corners is maintained and there is no redundant tissue.

How to cite this article: Venkatramani H, Hosahalli G, Sabapathy SR. Technical tips in Managing Fingertip Injuries. J Kar Orth Assoc. 2016 Feb; 4(1): 60-63.